

IgA Nephropathy

By Jürgen Floege

IgA nephropathy (IgAN) is a disease with a highly diverse course, and, as such, by definition has always required a personalized or stratified approach (call it “precision” if you like the term).

At one end of the extreme are patients with isolated hematuria, little to no proteinuria, and normal GFR and blood pressure, who have been considered to have “benign IgAN” in the past. Here, recent Swedish data with 20 to 25 years of follow-up show that about a third of these patients will experience spontaneous remission, another third to one-half have persistent urinary abnormalities but preserved GFR, and a quarter will experience chronic kidney disease (CKD) with 5% in CKD stages 4 to 5 (1). The bad news is that these 5% cannot be identified prospectively; thus, prolonged follow-up of such early IgAN patients is necessary.

At the other end of the extreme are the very rare patients with a vasculitic course of IgAN, who have a dismal renal prognosis with and without immunosuppression (2). These patients should not be confused with the IgAN patient with few crescents in the biopsy specimen but a stable GFR. Although large recent studies identify crescents as an adverse prognostic sign (3), it is important to realize that crescents can also occur in the “benign IgAN” group described above (4). Thus, crescents do not equal rapidly progressive glomerulonephritis in IgAN, they do not necessarily require immunosuppression, and many individuals will likely resolve with adequate supportive therapy, in particular, blood pressure reduction. In such patients, the clinical course rather than the biopsy should be the main criterion in designing rational therapeutic approaches.

The typical IgAN patient coming to the attention of a nephrologist is in the middle of the above extremes, i.e., has some proteinuria (usually non-nephrotic), microhematuria, and hypertension, and often has already lost a significant amount of GFR. In these patients, a comprehensive supportive approach—not just “give an ACE inhibitor”—can markedly slow down progression of the disease, and such patients derive no added benefit from immunosuppressive therapy but rather just experience more adverse events (5).

In Asian patients with a high average proteinuria (2.4 g/day) and a baseline GFR around 60 mL/min/1.73 m², systemic high-dose corticosteroid therapy slowed down progressive GFR loss, but that recent trial had to be terminated early because of an excess of adverse, sometimes lethal, events (6). A follow-up study (TESTING 2) with a lower corticosteroid dose

has started. An emerging alternative option is intestinal steroid therapy using enteric-coated budesonide (7). The rationale of this therapy is based on some evidence for a disturbed intestinal mucosal barrier in IgAN. A phase III trial with that compound has recently started. Other immunosuppressive agents, including rituximab, mycophenolate mofetil, azathioprine, cyclophosphamide, and some newer agents so far have not yielded consistent therapeutic benefit. Whether ethnicity should affect the choice of immunosuppression is not known.

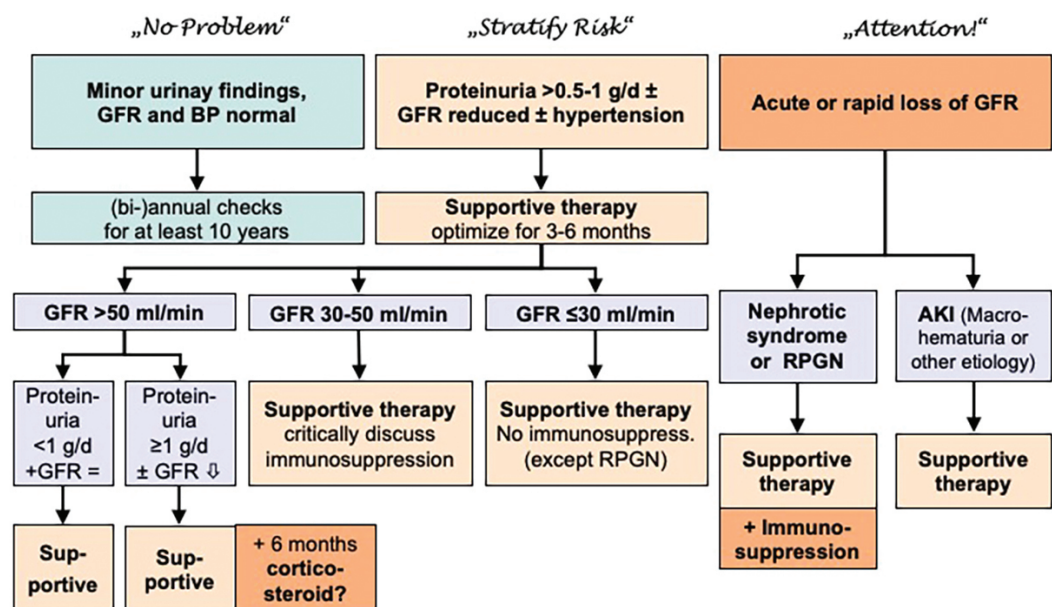
Our stratified approach to the therapy of IgAN is shown in Figure 1. Currently, the 2012 KDIGO guidelines on the treatment of glomerular disease are being updated; publication can be expected in mid-2019. ■

Jürgen Floege, MD, is associated with the Department of Nephrology and Clinical Immunology, RWTH University Hospital Aachen, Germany.

References

1. Knoop T, et al. Long-term outcome in 145 patients with assumed benign immunoglobulin A nephropathy. *Nephrol Dial Transplant* 2017; 32:1841–1850.
2. Lv J, et al. Prediction of outcomes in crescentic IgA nephropathy in a multicenter cohort study. *J Am Soc Nephrol* 2013; 24:2118–2125.
3. Haas M, et al. A multicenter study of the predictive value of crescents in IgA nephropathy. *J Am Soc Nephrol* 2017; 28:691–701.
4. Liu H, et al. Renal biopsy findings of patients presenting with isolated hematuria: Disease associations. *Am J Nephrol* 2012; 36:377–385.
5. Rauen T, et al. Intensive supportive care plus immunosuppression in IgA nephropathy. *N Engl J Med* 2015; 373:2225–2236.
6. Lv J, et al. Effect of oral methylprednisolone on clinical outcomes in patients with IgA nephropathy: The TESTING randomized clinical trial. *JAMA* 2017; 318:432–442.
7. Fellstrom BC, et al. Targeted-release budesonide versus placebo in patients with IgA nephropathy (NEFIGAN): A double-blind, randomised, placebo-controlled phase 2b trial. *Lancet* 2017; 389:2117–2127.
8. Floege J, Eitner F. Current therapy for IgA nephropathy. *J Am Soc Nephrol* 2011; 22:1785–1794.


Figure 1. Synopsis of suggested therapeutic approaches to patients with IgAN depending on clinical setting



Modified with permission from Floege and Eitner (8).

RENEW TODAY

Continue to Help Lead the Fight Against Kidney Diseases



Renew your membership for 2019 and continue to help lead the fight against kidney diseases. ASN member benefits include publication subscriptions, educational event registration discounts, complimentary access to self-assessment programs, and more.

All ASN membership types can renew quickly and easily online at www.asn-online.org/renew.